

ViewPoint 6

GE Healthcare



Date: 8/24/2010

Early Pregnancy Assessment

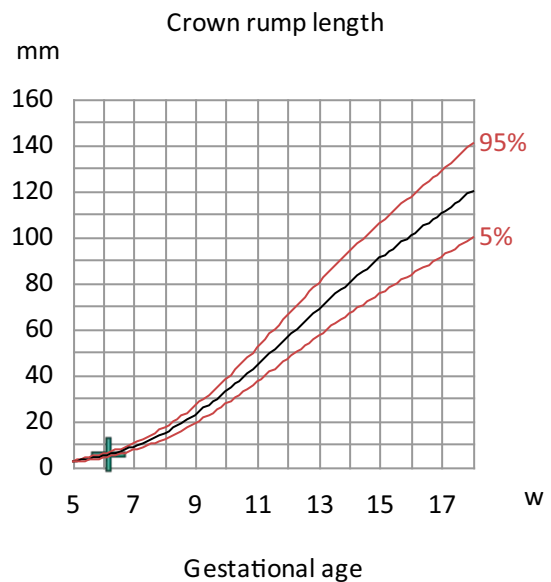
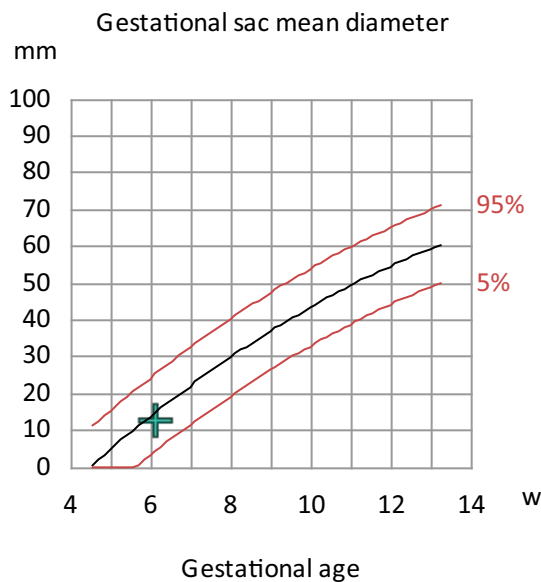
Indication First trimester screening.
Method Transabdominal and transvaginal ultrasound examination. Good view.
Pregnancy Singleton pregnancy. 1 gestational sac.
Dating

| | Date | Details | Gest. Age | EDC |
|---------------|--|---------------|-----------|-----------|
| LMP | 7/15/2003 | regular cycle | | |
| Agreed dating | Performed on 8/24/2010, based on ultrasound (GS) | | 6 w + 1 d | 4/18/2011 |

Assessment Gestational sac: visualized. Location: intrauterine.
 Yolk sac: visualized.
 Embryo: visualized.
 Cardiac activity: present. FHR: 160 bpm.
 Early placenta: anterior.

| | | | |
|-----|---------|-------|---------------|
| GS | 13.0 mm | 6w 1d | 40 % Rempen |
| YS | 4.7 mm | | 70 % Grisolia |
| CRL | 6.0 mm | 6w 2d | 97 % Hadlock |

Impression Normal intrauterine pregnancy.
Follow-up Repeat evaluation for detailed fetal survey is recommended.



S. Fox
 Sonographer

Dr. B. Winter
 Performing physician